



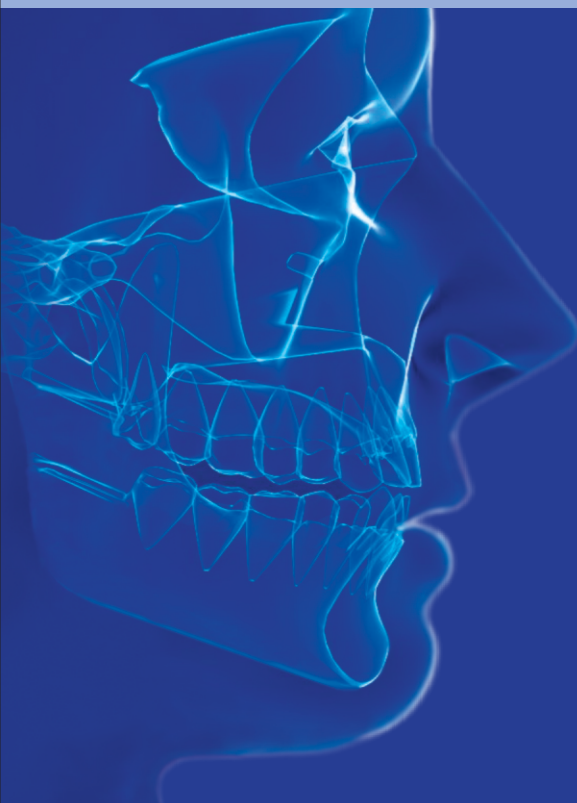# ams

## Annals of Maxillofacial Surgery

Official Publication of The Indian Academy of Maxillofacial Surgery

[www.amsjournal.com](http://www.amsjournal.com)

Estd : 1996



Wolters Kluwer  
Health

Medknow

# Degloving facial injury treated with hydroconductive dressing

## Access this article online

### Website:

www.amsjournal.com

### DOI:

10.4103/2231-0746.110073

### Quick Response Code:



Colin Perumal, Michael Bouckaert, Martin Robson<sup>1</sup>

Department of Maxillofacial and Oral Surgery, Medical University of South Africa, University of Limpopo, Republic of South Africa, <sup>1</sup>University of South Florida, Tampa, Florida, United States of America

### Address for correspondence:

Dr. Colin Perumal, Senior registrar/houseman-Department of Maxillofacial and Oral Surgery, Medical University of South Africa, University of Limpopo, Republic of South Africa.  
E-mail: coljer@tiscali.co.za

## ABSTRACT

Complex, open maxillofacial fractures are often accompanied by extensive contamination, crush, or avulsion of the overlying soft tissue, there have been two alternatives to treatment: either radical debridement of all contaminated tissue, fixation of the underlying fractures, and soft tissue closure by pedicle flap or graft is done; or more conservative debridement is repeated multiple times until the contaminated tissue is removed and fracture fixation is deemed safe. Debridement is usually accomplished by sharp debridement or with high-pressure intermittent irrigation or some combination of both modalities. The problems with this standard treatment in the face are that facial features may be distorted, superficial branches of the facial and/or trigeminal nerve can be inadvertently sacrificed (even with the use of nerve stimulators), and scarring can distort contours and radically change facial appearance. A serious facial degloving injury with necrotic malodorous tissue and no clear anatomical delineations demanded special attention. The purpose of this report is to demonstrate the management of a soft tissue avulsive contaminated injury of the face with underlying maxillofacial fractures.

**Keywords:** Avulsive facial wound, hydroconductive dressing, septic

## INTRODUCTION

We report a case of complex maxillofacial injury with avulsion of the soft tissue, which was treated in a more conservative manner that avoided many of the complications.<sup>[1]</sup> The case was that of a 39-year-old female who presented to the emergency department 8 days after being involved in a motor vehicle accident, which had caused a severe disruption of the soft tissue architecture of the left face associated with a malodorous septic wound consisting of loose bone fragments, grass, pieces of glass, stone, and sand [Figure 1].

Clinical examination suggested a fracture of the left lateral orbital margin. There were no cranial nerve defects. Because of the severe degree of contamination, radical debridement would have required to put the wound into bacterial balance to allow successful closure. This would have necessitated the undesirable removal of the exposed superficial nerve branches.

We elected to do minimal debridement of the soft tissue and perform reduction and fixation of the orbital rim to reestablish facial contour. A new hydroconductive dressing Drawtex (SteadMed Medical, LLC. Fort Worth, Texas 76102) was used to treat the soft tissue wound. This dressing has been demonstrated to remove exudate, debris, bacteria, biofilm, and cytokines deleterious to wound healing.<sup>[2-5]</sup> The Drawtex dressing was initially changed daily and the frequency was decreased as the wound improved [Figures 2a-d and 3a-c].

Serial photographs, wound measurements, and Elixr analyses were performed. Wound bed analysis from photographic images was done (Imago Care Ltd, London, UK). Elixr is a statistical pattern-recognition algorithm that classifies each wound color pixel in a wound image, providing a documented area measurement variance of only 1% (with flat wound images) to 5% (with rounded wound images) was used. It also divides a wound into three tissue type classifications: Necrotic tissue

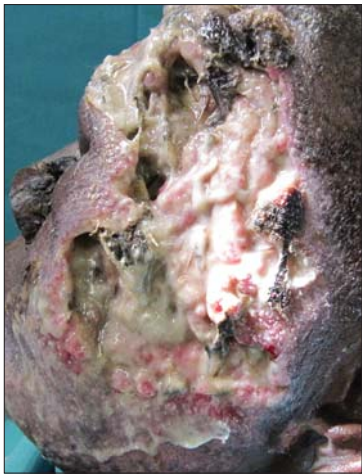

Figure 1: Wound on presentation

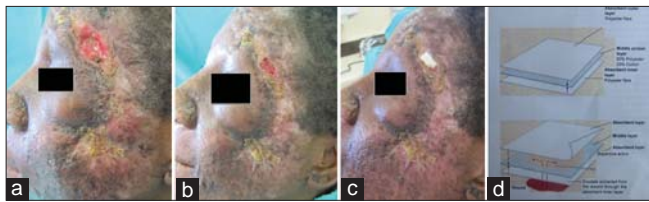

Figure 3 (a-d): Representation of progressive healing, structure of drawtex

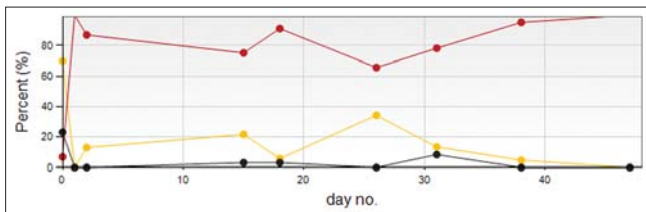


Figure 5: Tissue analysis graph (Yellow = slough, Black = Eschar, Red = granulation)

is represented in black color; fibrin and slough in yellow; and granulation tissue in red in a digitized wound photograph. Accurate readings of granulation, slough and eschar found in the wound bed were recorded [Figures 4 and 5].

The wound trajectory progressed to total healing by the 33<sup>rd</sup> day. No further debridement of the soft tissue was required. Patient was subsequently lost to long-term follow-up when she failed to return and efforts to locate her were unsuccessful.

## DISCUSSION

Hydroconductive dressings are a new class of wound dressing developed to aid wound healing.<sup>61</sup> Drawtex is composed of a combination of two types of absorbent, cross-action structure that creates the ability to move large volumes of fluid, debris, and other deterrents to healing from the wound and into the dressing. This hydroconductive action allows the dressing to lift, hold, and transfer the wound exudate both horizontally and vertically. Even

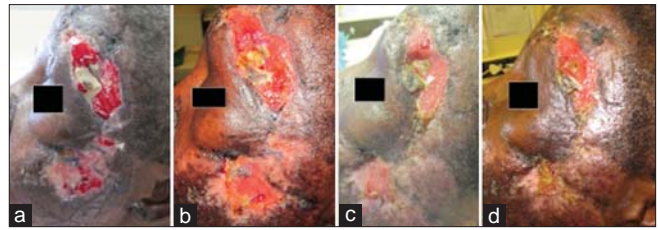


Figure 2 (a-d): Wound healing after successive dressing changes from Day 15 to 30

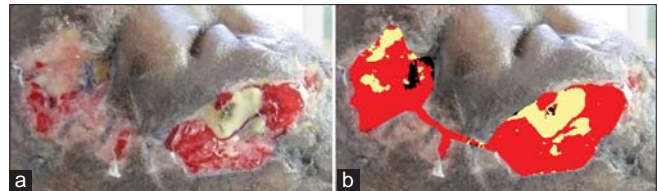


Figure 4: Wound gallery analysis (Yellow = slough, Black = Eschar, Red = granulation)

when completely saturated, the Drawtex dressing maintains its integrity, stays in place and remains intact so it can be easily removed in one piece. No dressing particles are left in the wound.

This case report demonstrates the use of a new hydroconductive dressing to perform many of the functions of surgical debridement. In this case, it allowed the wound to progress with minimum loss of soft tissue, without losing structures such as superficial peripheral nerves, and negated the need for tertiary wound closure by a pedicle flap or skin graft.

## REFERENCES

1. Perumal CJ, Robson M. Use of a hydroconductive dressing to treat a traumatic avulsive injury to the face-A case report. *Eplasty* 2012;12:e32.
2. Truhan O, Moffatt LT, Robson MC, Jordan MH, Shupp JW. *In vivo* and *in vitro* evaluation of the properties of drawtex levafiber wound dressing in an infected burn wound model. Poster presentation at the SAWC-WHS Annual meeting, Atlanta, GA, 2012.
3. Ochs D, Donate G, Abercrombie M, Mannari R, Wright T, Payne WG, et al. Evaluation of mechanisms of action of a hydroconductive dressing for chronic Wounds. Poster presentation at the SAWC-WHS Annual Meeting, Atlanta, GA, 2012.
4. Wolcott R, Dowd S. Drawtex Effects on VLU healing and biofilm. Poster presentation. 24<sup>th</sup> 96 Annual Symposium on Advanced Wound Care and the Wound Healing Society Meeting. Dallas, TX. 2011.
5. Lichtenstein P, Wendelken M, Alvarez O. Detoxication of venous ulcers with a novel hydroconductive wound dressing that transfers chronic wound fluid away from the wound. Poster presentation. 24<sup>th</sup> Annual Symposium on Advanced Wound Care and the Wound Healing Society Meeting. Dallas, TX. 2011.
6. Couch KS. Discovering hydroconductive dressings. *Ostomy Wound Management* 2012;58:8-10.

**Cite this article as:** Perumal C, Bouckaert M, Robson M. Degloving facial injury treated with hydroconductive dressing. *Ann Maxillofac Surg* 2013;3:87-8.

**Source of Support:** Nil, **Conflict of Interest:** No.