

Wound Fluid Management in Wound Care: The Role of a Hydroconductive Dressing

Tom Wolvos MS, MD, FACS¹ and Matthew Livingston RN, BSN, CWS, ACHRN²

WOUNDS 2013;25(1):XXX-XXX

From the ¹Scottsdale Healthcare Osborn Medical Center, Scottsdale, AZ; ²Paradise Valley Wound Center, Paradise Valley, AZ

Address correspondence to:

Tom Wolvos MS, MD, FACS

Scottsdale Surgical Consultants

3501 N. Scottsdale Rd #234

Scottsdale, AZ 85251

twolvosmd@scottsdaleurgical.com

Abstract: A case series was conducted to evaluate the clinical experience with a new hydroconductive wound dressing, that appears to help facilitate the removal of necrotic tissue and other deterrents to wound healing while preserving healthy granulation tissue in a wound. Eight patients were treated with the dressing which has a proprietary technology that draws fluid away from the wound. The dressing was used on a variety of wound types and all wounds went on to heal by secondary intention. There were no adverse effects noted by any patient in the case series. Larger patient studies are needed to corroborate the positive clinical results that were observed in this series of patients.

Although writings pertaining to wound care date back several millennia, the development of advanced wound dressings is a relatively recent phenomenon.

One purpose of a dressing is to provide an environment favorable for wound healing. A dressing may provide moisture to a dry wound or remove fluid from a highly exudative wound. Dressings may also actively help debride wounds.

A hydroconductive dressing (Drawtex[®], SteadMed Medical, Fort Worth, TX) draws fluid away from the wound using capillary action while retaining its integrity.¹ The dressing appears to debride wounds, helping remove adherent slough and debris, and independent digital wound bed analysis observed preservation of healthy granulation tissue.² It has been observed to also absorb excessive wound exudate containing bacteria and deleterious cytokines, leaving a more favorable wound healing environment.^{3,4} The purpose of this case series was to report healing and debridement outcomes of patients whose wounds were managed with this dressing.

Methods

A hydroconductive dressing was used in a case series of 8 patients with wounds that had adherent slough and necrotic tissue, and varying levels of exudate, from minimal to highly exudating. The 8 patients (3 males, 5 females) ranged in age from 49 years to 97 years. They were treated with a hydroconductive dressing as the primary wound dressing for 3 consecutive weeks (Table 1). The dressing was cut to ensure it was in contact with the base of the wound. Two of the patients were immunosuppressed, one to treat rheumatoid arthritis, and another due to kidney transplant. No other method of

Table 1. Patient demographic information.

Patient	Age (yrs.)	Gender	Wound Type	Adjuvant Treatment	Immunosuppressed
1	76	Female	Traumatic skin tear	Mupirocin/tubi-grip	Yes (rheumatoid arthritis)
2	85	Female	Traumatic foot	Silver sulfadiazine	No
3	97	Female	Traumatic skin tear	Neosporin	No
4	67	Male	Traumatic leg	Collagenase	Yes (kidney transplant)
5	81	Female	Traumatic skin tear	None	No
6	49	Male	Traumatic laceration	Silver sulfadiazine	No
7	81	Female	Traumatic skin tear	Silver sulfadiazine	No
8	65	Male	Venous leg ulcer	Compression (Profore)	No

Case Study 1

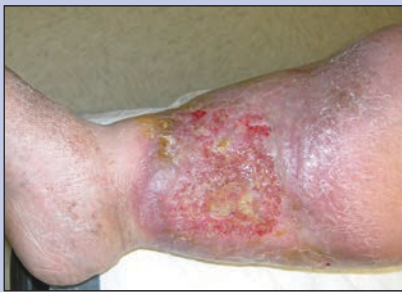

Figure 1. Highly exuding venous leg ulcer (1/3/11 –Drawtex week 0)

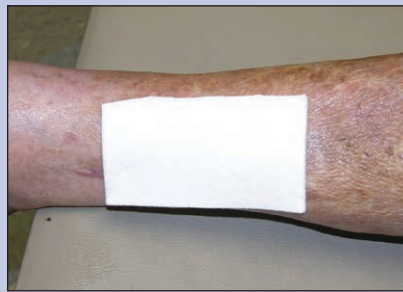

Figure 2. Hydroconductive dressing in place

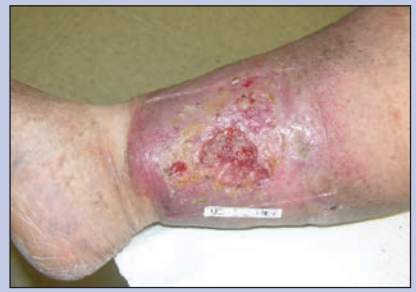

Figure 3. Healing wound 1/17/11 Drawtex week 2

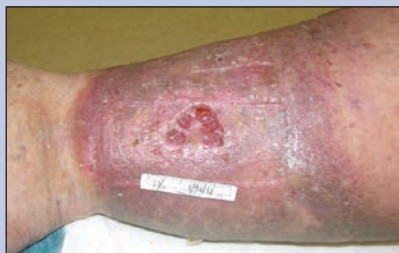

Figure 4. Highly exuding venous leg ulcer (1/3/11 –Drawtex week 0)

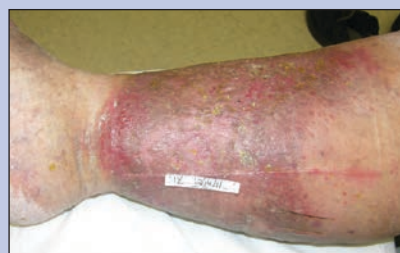

Figure 5. Healed wound 2/14/11 Drawtex week 6

debridement was used in the study except in patient 8, whose wound was gently wiped with sterile gauze at dressing changes. Compression was used where indicated. The dressing was cut to ensure it was in contact with the base of the wound. In highly exuding wounds, the dressing was frequently used by stacking more than 1 layer. In dry wounds, an silver sulfadiazine cream 1% (Silvadene®, Pfizer, New York, NY) was used in conjunction

with the dressing to help keep the wound moist. Dressings were typically changed daily, but in some situations, such as with venous leg ulcers, it was left in place for up to 1 week under compression. During the 3-week period in which the patients were studied, no other form of debridement was used, except in 1 case, where the wound was minimally debrided with sterile gauze. Digital photos were taken once a week for 3 weeks and submitted

Case Study 2

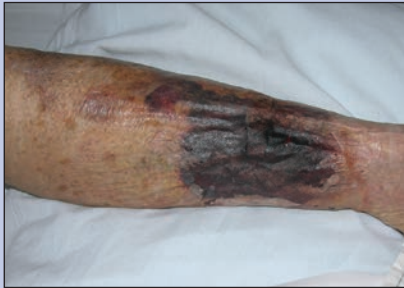

Figure 1. Initial photo after drainage in the hospital 1/14/11

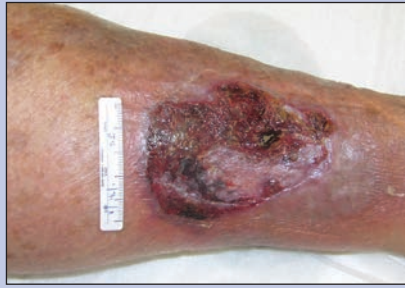

Figure 2. Healing wound 1/31/11 Drawtex week 0

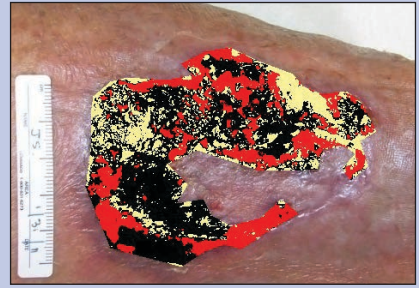

Figure 2a. Digital wound analysis 1/31/11. Drawtex week 0. The color code is: necrotic tissue represented as a black color; yellow represents fibrin and slough; and red represents granulation tissue.

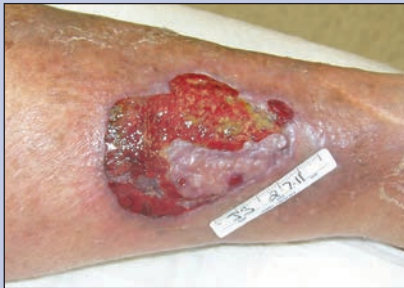

Figure 3. Wound progression 2/7/11 Drawtex week 1

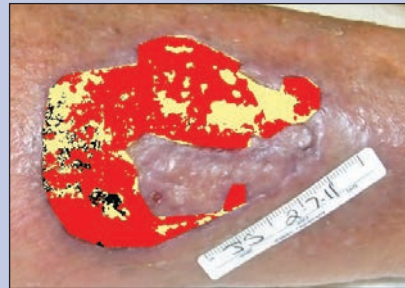


Figure 3a. Digital wound analysis 2/7/11. Drawtex week 1. Necrotic tissue represented as a black color, yellow represents fibrin and slough, and red represents granulation tissue.

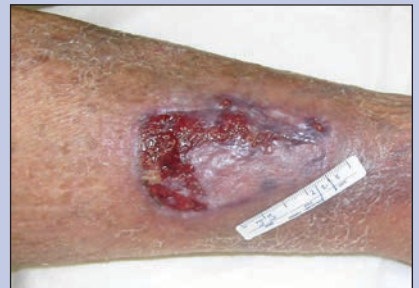

Figure 4. Healing wound 2/21/11 Drawtex week 3

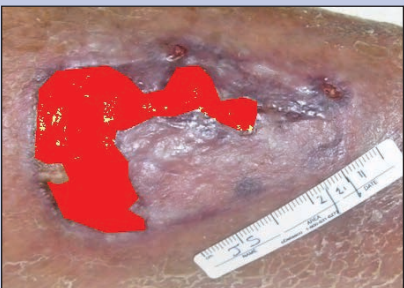

Figure 4a. Digital wound analysis 2/21/11. Necrotic tissue represented as a black color, yellow represents fibrin and slough and red represents granulation tissue.

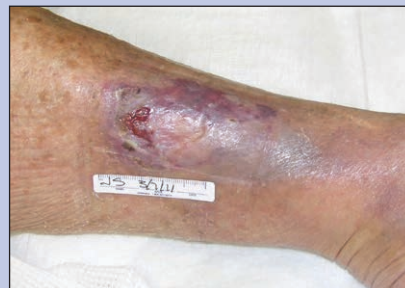

Figure 5. Healing wound 3/7/11 Drawtex week 5

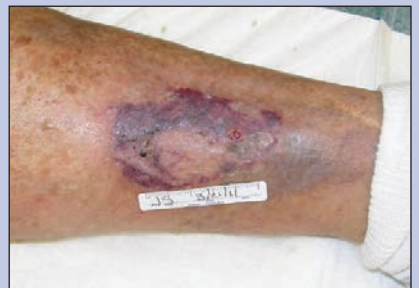

Figure 6. Healing wound 3/21/11 Drawtex week 7

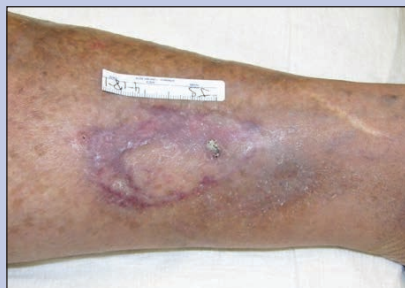

Figure 7. Healed wound 4/18/11

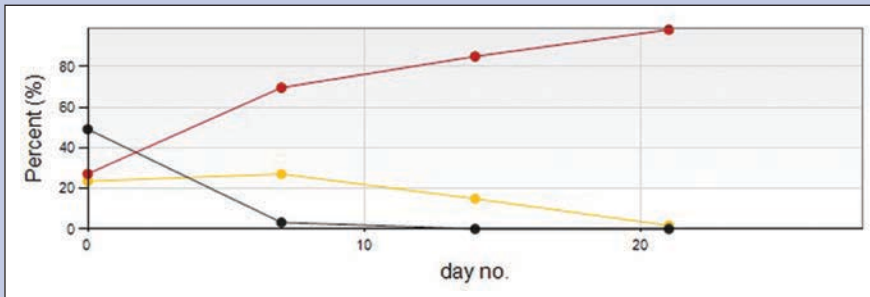


Figure 8. Area graph of this case. Necrotic tissue represented as a black color, yellow represents fibrin and slough, and red represents granulation tissue.

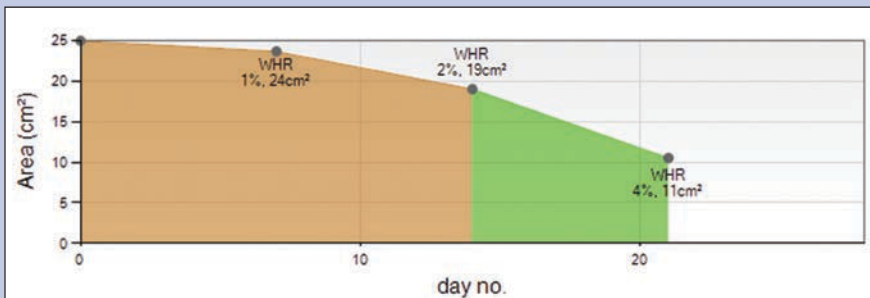


Figure 9. Dimension tissue trend graph for this case. Necrotic tissue represented as a black color, yellow represents fibrin and slough, and red represents granulation tissue.

for independent wound bed analysis by an individual at Imago Care Ltd in England, who was blinded to the study, to document changes in wound area and in percentage of necrotic tissue, slough, and granulation tissue present.

Since clinician observation is a subjective evaluation, an advanced pattern recognition software algorithm that uses artificial intelligence to analyze digital wound images and provide accurate wound measurements and tissue analysis was used (iCLR technology®, powered by Elixr, Imago Care Ltd, England). This technology calculates wound measurements including area, circumference, width, and height. It also divides a wound into 3 tissue-type classifications in the digitized wound photograph: necrotic tissue, represented as a black color; fibrin and slough, represented as a yellow color; and granulation tissue, represented as a red color. This algorithm has been demonstrated to be objective, reliable, reproducible, qualitative, and quantitative.⁵

Results

Eight patients were treated with a hydroconductive dressing as the primary dressing for 3 consecutive weeks. No complications were observed over the course of the trial and all patients tolerated use of the dressing. At the

completion of the trial, use of the dressing was continued and all of the wounds went on to complete healing.

Independent digital wound analysis demonstrated preservation of healthy tissue while documenting reduction of adherent fibrin, slough, and necrotic tissue. The average area of necrotic tissue and slough of all the patients was reduced 36% by week 1, 52% by week 2, and 77% by week 3 (Figure 1). There was also a corresponding reduction of wound area: 15% by week 1, 35% by week 2, and 47% by week 3 (Figure 2).

Discussion

A tenet of modern wound care is that the principal purpose of a dressing is to provide an environment that will enhance wound healing

while also protecting the wound from outside elements.⁶ An ideal dressing should maintain a moist wound environment while removing excess exudate and toxins. It should be comfortable for the patient, act as a barrier to prevent a secondary infection, and maintain its integrity when moist.^{7,8}

Recently a variety of specialized wound dressings have been developed that can be grouped into categories according to their function and mechanism of action. A detailed listing of dressings, their uses, indications, advantages, and disadvantages has been published.^{6,9} The preferred dressing for a specific clinical situation can be determined after an assessment of the wound characteristics and the goals of treatment.

Wounds can be divided into groups by their etiology, amount and nature of exudate, degree of contamination and infection, and size and depth of injury, to name a few. It is important to recognize that the characteristics of the wound and medical status of the patient changes over time. This may require modification of the dressing as the wound passes through different phases of wound healing.⁶ Proposed protocols matching wound types with appropriate dressings have been published.¹⁰

Bates-Jensen has proposed a rating system to quantify

Case Study 3

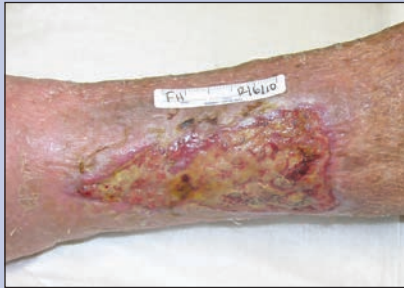

Figure 1. Traumatic skin tear right lower leg 12/6/10.

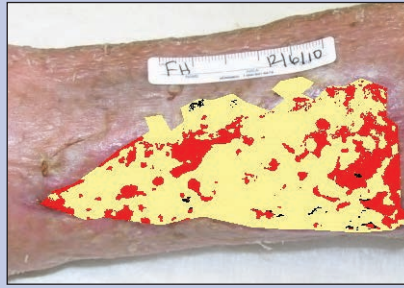


Figure 2. F.H. week 0 Digital analysis. Digital color code: Necrotic tissue represented as a black color, yellow represents fibrin and slough and red represents granulation tissue.

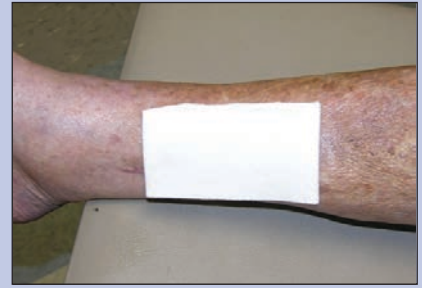

Figure 3. Hydroconductive wound in place.

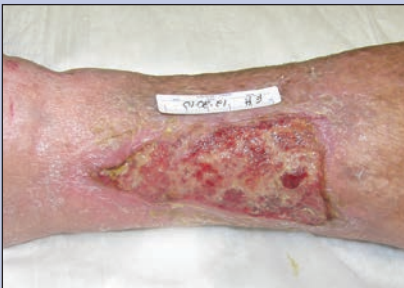

Figure 4. Wound progressing 12/20/10 week 2

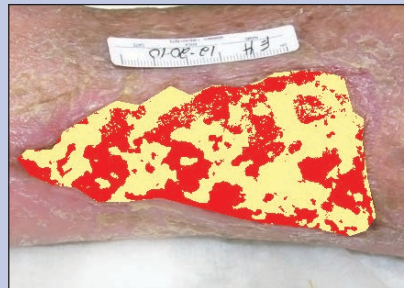


Figure 4a. F.H. Week 2 digital analysis. Necrotic tissue represented as a black color, yellow represents fibrin and slough, and red represents granulation tissue.

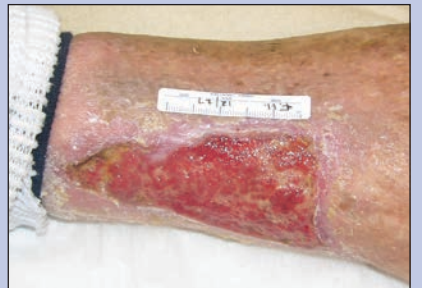

Figure 6. Wound healing 12/27/10 Drawtex week 3

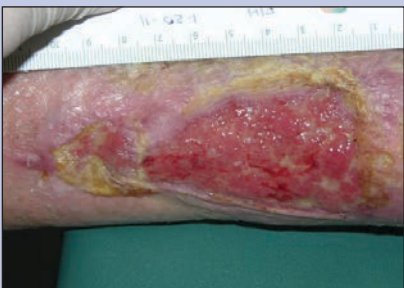

Figure 7. Wound healing 1/20/11 Drawtex week 6

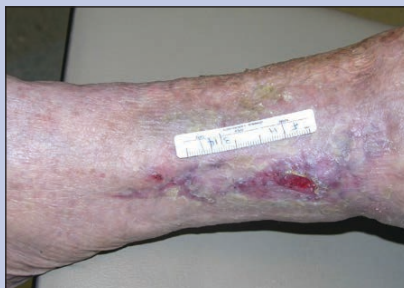

Figure 8. Wound healing 3/14/11 Drawtex week 15

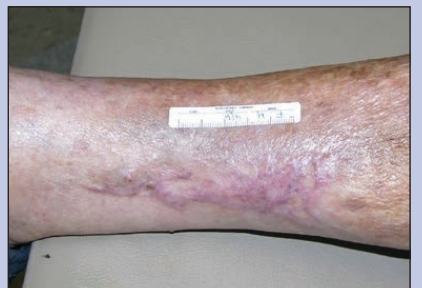

Figure 9. Wound healed 4/6/11

the amount of fluid in a wound bed.¹¹ In dry wounds, a moist wound healing environment can be provided by a variety of dressings including hydrocolloids, alginates, hydrogels, and hydropolymer foams. At the other extreme, control of fluid in a highly exudative wound can be a significant challenge but is important to control so as to promote wound healing and to prevent maceration of the periwound tissues. Depending on the exudate levels the

appropriate dressing may have occlusive, semiocclusive, absorptive, hydrating, autolytic debriding, or hemostatic characteristics.¹² The moisture control can be passive, where the fluid is simply absorbed into the primary dressing, or active, where the fluid is actively transported away from the wound and bound into the dressing.

Wound exudate consists of water containing electrolytes, nutrients, white blood cells, inflammatory media-

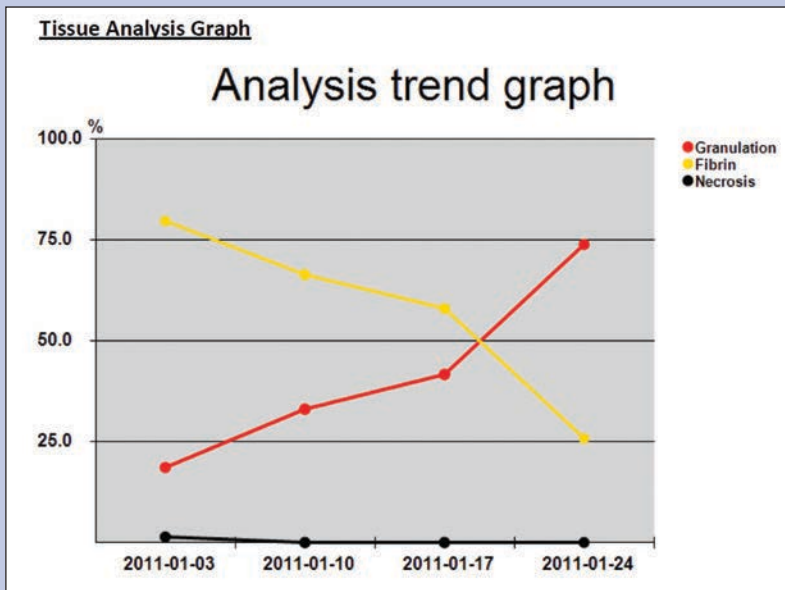


Figure 10. Analysis trend graph for this case weeks --- 0 – 3.

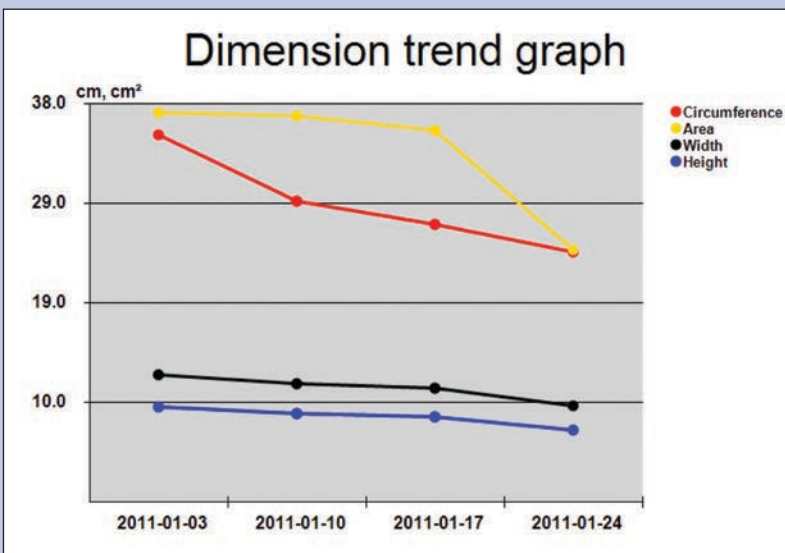


Figure 11. Dimension trend graph for this case --- weeks 0 - 3. Necrotic tissue represented as a black color, yellow represents fibrin and slough, and red represents granulation tissue.

in a vicious cycle of tissue breakdown and chronic inflammation.

One of the goals of an advanced dressing may be to restore the normal balance of growth factors, cytokines, and proteolytic mediators in a wound bed to create a more favorable environment for wound healing.¹⁵ For example, specialized dressings may remove the MMPs from the wound by binding and sequestering them in the dressing or the MMPs may be actively drawn away from the wound into a highly absorbent dressing. To be effective, advanced wound dressings, like other advanced wound modalities, must be combined with clinically accepted basic wound care.¹⁶

The authors used a hydroconductive, nonadherent wound dressing (Drawtex) with a technology that actively draws fluid and debris into the wound, trapping it in the dressing. It can absorb up to 150 cc/h of fluid.¹⁷ If multiple layers of this dressing are used, the fluid is wicked to the outermost layer of the dressing. The fluid is drawn both laterally from the wound and vertically to dressings stacked on top.^{18,19}

In this series of 8 patients, “hydroconductive debridement” performed by this dressing selectively removed undesirable tissue leaving intact healthy tissue as demonstrated in serial digital photo analysis. The healthy granulation tissue was preserved over time and actually increased in volume while the necrotic tissue and slough was selectively debrided decreasing its volume in the wound analysis. Mechanical debridement (wiping the wound with a piece of sterile gauze), was used in 1 patient (patient #

8) and worked in a complementary nature with the hydroconductive debridement properties of the dressing.

Hydroconductive debridement in this case series demonstrated an average reduction in the wound bed area by 44% over 3 weeks of dressing application. The series also demonstrated an average reduction in necrotic tissue of 77% over 3 weeks. This compares to a study by Pullen et al 20 where collagenase (an enzymatic debrider), showed

tors, protein digestive enzymes, and growth factors.¹³ An analysis of wound fluid shows differences in composition when comparing the fluid from acute and chronic wounds. Chronic wound fluid shows an increase in levels of matrix metalloproteinases (MMPs), and serine proteinases, which may be destructive in nature to chronic wounds.¹⁴ These enzymes degrade proteins including collagen and growth factors. In chronic wounds, this results

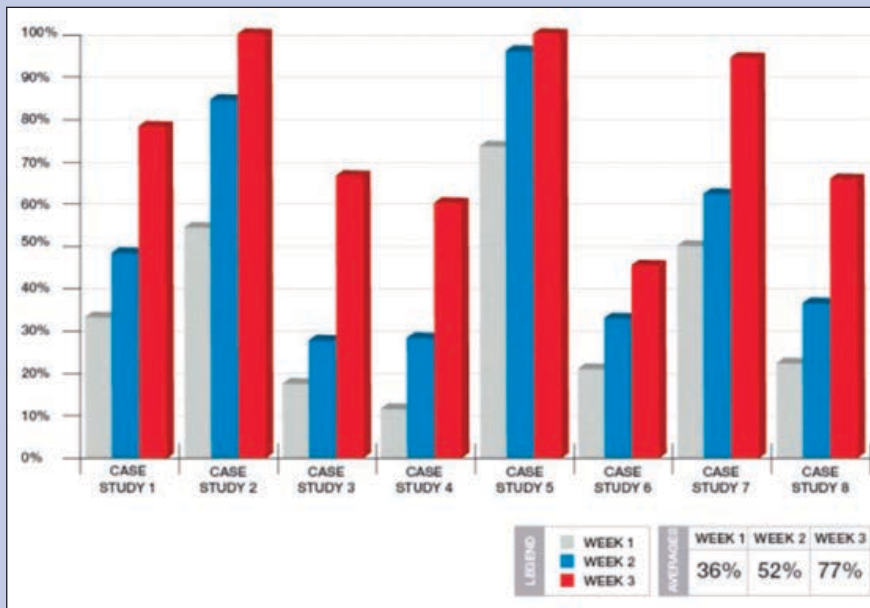


Figure 12. Percentage Reduction in Combined Slough and Eschar.

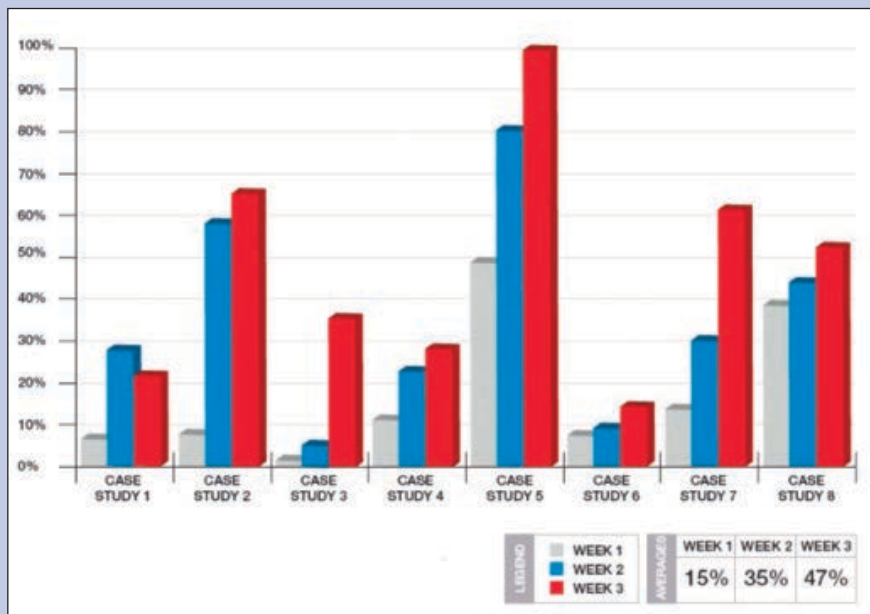


Figure 13. Reduction in Wound Area Percentage.

only 46.7% of patients had removal of 50% or more of the nonviable tissue in the wounds over a maximum of 4 weeks.

This dressing is highly absorbent and may act to detoxify the wound by removing adherent slough, necrotic tissue, bacteria and exudate. The exudate removed may contain factors such as proteases and other factors or toxins that may inhibit normal wound healing.⁴ MMP-9 has been demonstrated to be drawn into the dressing and is active-

ly transported up to 7 cm away from the wound edge.²¹ The effect of decreasing the proteases in a wound may depend on the balance that is left. It has been demonstrated that poor healing of diabetic foot ulcers may be seen when the levels of MMP-8 and MMP-9 have not decreased with treatment.²² However drawing desirable autolytic enzymes away from the wound may be deleterious to wound healing.²³

The fluid removed may also contain the plasma necessary to act as the nutritional substrate to maintain the viability of a biofilm. Rapid removal of this exudate may then diminish the biofilm's pathogenic activity in the wound, leading to improved wound healing.²⁴

Larger numbers of patients are needed to confirm the results of this study and help to further identify the complete role of this hydroconductive dressing in wound care.

Conclusions

A new category of hydroconductive dressing was used as the primary wound care for a case series of 8 patients with a variety of wound types. This dressing proved to be comfortable and easy for patients to use. Its use resulted in debridement of necrotic tissue and slough from the wound bed. Using an artificial

intelligent pattern recognition algorithm software program, areas in the wounds containing healthy granulation tissue were observed to be preserved over time and expanded into areas that were debrided of fibrin, slough, and harmful cytokines. It protected the wound from outside contamination and detoxified the wound by decreasing levels of toxins, proteases, and the nutrients necessary to maintain a biofilm.

All wounds in this series healed without any adverse

events. More experience is needed to confirm the authors' findings and further define this dressing's role in advanced wound care. Once the role is clearly defined, a randomized clinical trial comparing this hydroconductive dressing to autolytic debridement and 1 or more other advanced dressings may be useful.

References

- Livingston M, Wolvos T. Hydroconductive Debridement: a new perspective in reducing slough and necrotic tissue. Poster presented at: 24th Annual Symposium on Advanced Wound Care and the Wound Healing Society Meeting; April 14-17, 2011: Dallas, TX.
- Wolvos, T. Analysis of wound bed documentation in advanced wound care using Drawtex, a hydroconductive dressing with LevaFiber technology. *WOUNDS*, 2012; 9(suppl):9-10.
- Ortiz R, Moffatt L, Robson M, Jordan M, and Shupp J. In vivo and in vitro evaluation of the properties of Drawtex LevaFiber wound dressing in an infected burn wound model. *WOUNDS*. 2012; 9 (suppl):3-5.
- Wendelken M, Lichtenstein P, DeGroat K, and Alvarez O. Detoxification of venous leg ulcers with a novel hydroconductive wound dressing that absorbs and transports chronic wound fluid away from the wound. *WOUNDS*. 2012;9(suppl):11-13.
- Application & Validation of a Unique Wound Image Analysis Tool. Elixr® & iCLR Technology® Developers. Imago Care Ltd. Product information available at: <http://www.digitalhealthcaresolutions.co.uk/>
- Mendez-Eastman S. Wound dressing categories. *Plast Surg Nurs*. 2005;25(2):95-99.
- Donnelly J. Wound healing-from poultices to maggots. (a short synopsis of wound healing throughout the ages). *Ulster Med J*. 1998;(Suppl 1):47-51.
- Turner T. The Development of Wound Management Products. In Krasner D, Wilson, D, eds. *Chronic Wound Care: A Source Book for Healthcare Professionals*. 1st ed. King of Prussia, PA: Health Management Publication; 1990
- Thomas-Hess C. *Clinical Guide to Skin and Wound Care*. 7th ed, Philadelphia, PA: Lippincott Williams & Wilkins; 2012
- Livingston M, Wolvos T. *Scottsdale Wound Management Guide 2009*. HMP Communications Publisher. p 79-106
- Bates-Jensen B, Ovington L. Management of Exudate and Infection In Sussman C, Bates-Jenson, B eds. *Wound Care: A Collaborative Practice Manual for Health Professionals*. 3rd ed. Lippincott Williams & Wilkins; 2007.
- Okan D, Woo K, Ayello E, Sibbald G. The role of moisture balance in wound healing. *Adv Skin Wound Care*. 2007;20(1):39-55.
- M Romanelli, K Vowden, D Weir. Exudate Management Made Easy. *Wounds International* 2010; 1(2): 1-6. Accessed December 26, 2012: http://www.woundsinternational.com/pdf/content_8812.pdf
- Wysocki AB, Kusakabe AO, Chang S, Tuan TL. Temporal expression of urokinase plasminogen activator, plasminogen activator inhibitor and gelatinase-B inhibitor in chronic wound fluid switches from a chronic to acute wound profile with progression to healing. *Wound Repair Regen*. 1999;7(3):154-165.
- Staiano-Coico L, Higgins P, Schwartz SB, Zimm AJ, Goncalves J. Wound fluids: a reflection of the state of wound healing. *Ostomy Wound Manage*. 2000;46(suppl 1A):85S-95S.
- Wu S, Marston W, Armstrong DG. Wound care: The role of advance wound healing technologies. *J Vasc Surg*. 2010;52(3 Suppl): 59S-66S.
- Personal communication Kobie Mouton, Director, Beier Drawtex Healthcare Ltd.
- Tests completed 5/6/11 by SABS Commercial, 1 Dr. Lategan Road, Groenkloof, Pretoria 0001, White paper.
- Product information. Drawtex. <http://www.steadmed.com/images/WoundTherapy/PrimaryDressings/Brochures/drawtexbrochure.pdf>
- Pullen R, Popp R, Volkens P, Fusgen I. Prospective randomized double-blind study of the wound debriding effects of collagenase and fibrinolysin/deoxyribonuclease in pressure ulcers. *Age Aging*. 2002;31(2):126-130.
- Lichtenstein P, Wendelken M, Alvarez O. Detoxification of venous ulcers with a novel hydroconductive wound dressing that transfers chronic wound fluid away from the wound. 2011. Poster presented at: 24th Annual Symposium on Advanced Wound Care and the Wound Healing Society Meeting; April 14-17, 2011: Dallas, TX.
- Muller M, Trocme C, Lardy B, Morel F, Halimi S, Benhamou PY. Matrix metalloproteinases and diabetic foot ulcers: the ratio of MMP-1 to TIMP-1 is a predictor of wound healing. *Diabet Med*. 2008;25(4):419-426.
- Edwards J, and Stapley S. Debridement of diabetic foot ulcers. *Cochrane Database Syst Rev*. 2010;(1):CD003556.
- Wolcott R. The effect of a hydroconductive dressing on the suppression of wound biofilm. *WOUNDS*. 2012;24(5):132-137.